

DOI: <https://doi.org/10.24297/ijct.v26i.9865>

A comprehensive, integrated study of the topographical anatomy of the clavicle, its biomechanical architecture and function; pathological anatomy of mid-shaft fractures and the decision-making about the surgical approach to mid-shaft fractures when applying an intramedullary implant:

Part 9. Newly conceived intramedullary implant designs for the fixation of mid-diaphyseal fractures of the clavicle

Gandhi, Harjeet Singh, MD, FRCS, FRCSC, MSc (Biomed. Eng)

Orthopaedic surgeon, Honorary Staff, Hamilton Health Sciences, Hamilton, ON, Canada

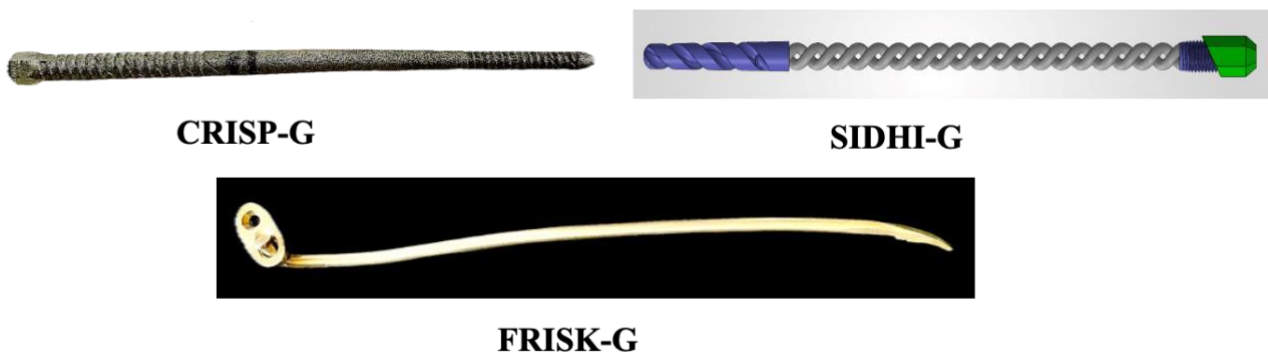Email: harjeetg52@yahoo.co.uk

Highlights: The newly conceived intramedullary implants are_

1. Clavicle reduction and intramedullary stabilization pin (CRISP-G®).
2. Self-drilling intramedullary double-helix implant (SIDHI-G®); and
3. Fracture reduction intramedullary stabilization kit (FRISK-G®).

Closing arguments: The clavicle is not a guardrail. The design and kinematics of the clavicle are far more precise and sophisticated. If the clavicle fracture is not restored to its original state, the monolithic gear train formed by the clavicle and the scapula becomes a two-bone problem. Clinically and kinematically, the glenohumeral articulation, as the surrogate of the clavicle, suffers the most.

Graphic abstract:



Keywords: Clavicle fracture, Clavicle implant, Fracture fixation, Intramedullary implant, Implant design, Implantology, Biomechanics.

1.0 Clavicle reduction and intramedullary stabilization pin (CRISP-G®):

CRISP-G is a cannulated device for closed reduction and fixation of mid-diaphyseal clavicle fractures of varying patterns (Fig. 1). This intramedullary device features a differential screw thread with a head to facilitate a



Figure 1. CRISP-G – Titanium additive manufactured prototype.

controlled approximation of the reduced and realigned fracture ends. It is not a compression device that provides rigid fixation of the major fragments but a semi-rigid bone-implant construct for approximation, realignment, and stability.

2.0 Biomechanical principle:

As the CRISP-G design provides biological fixation, an acute bone fracture heals naturally through a secondary bone healing process, forming a circumferential cuff of provisional woven callus under healthy biological conditions. Over time, the fracture zone remodels, and the bone returns to its normal function. The provisional callus matures under optimal mechanical conditions, including a 2mm interfragmentary gap, 2% strain, and three-dimensional

¹ CRISP-G is the intellectual property of the author.

dynamic loading at the fracture site. The maturing callus progressively strengthens and stiffens, gradually relieving the embedded intramedullary device of its load sharing role. This allows the healing bone callus to begin remodelling early under patient-specific physiological forces, a fundamental principle of Wolfe's Law and mechanostat theory of Frost (the structure and mass of the bone adapt to mechanical loads via a feedback mechanism). As movement and tissue strain gradually decrease at the fracture site, the strengthening callus takes over the function of the intramedullary implant.

3.0 Why develop CRISP-G:

Historically, clavicle fractures collapse due to telescoping of fragments over smaller-diameter smooth Kirschner wires and even smooth, flexible Titanium elastic nails of larger diameters, offering poor linear and rotational shear resistance, stiffness, and stability. There are migration and extrusion issues of the trailing ends, causing wound irritation and skin breakdown, necessitating early removal. Similarly, subcutaneous superior and anterior placement of the plates and screws irritates and rarely leads to breakdown of the surgical wound. A supposedly healed clavicle fracture, treated under conditions of absolute stability with rigid fixation and compression of the fracture fragments, becomes less cost effective when it requires a second surgery after a refracture.

The CRISP-G design is based on experience, using fully threaded, generic Steinmann pins with a major diameter of 4.0 to 5.0 mm and a trocar cutting end that requires pre-drilling for the preparation of the medulla. Implant-related complications, including subcutaneous irritation from the sharp cut end of the pin, serous discharge, and extrusion, led to an early removal. The tapered shaft of the CRISP-G is easier to negotiate around the curve, and a differential screw thread facilitates controlled approximation and graded compression of the fragments, and interference fit at the proximal end and a transitional fit at the distal end threads. This configuration increases torsional resistance and linear shear stresses, preventing telescoping of the fracture fragments and extrusion or shortening of the reduced clavicle.

4.0 Engineering design principles of CRISP-G:

Intramedullary implants cannot inherently resist torsional forces in a straight bone, necessitating interlocking screws. The ratio of pin diameter to bone canal is crucial for achieving an interference fit that increases torsional and translational shear stresses at the endosteal surface and provides at least two-point loading for stability depending on the bone architecture. The human femoral diaphysis has a complex three-dimensional geometry with biplanar anterior and lateral curvatures, and rarely a medial curvature (Imamura et al., 2021). These multiplanar curvatures support the three-point loading against the endosteum, thereby resisting the compression load on the intramedullary nail and dissipating the forces radially onto the cortex at the bone-implant interface. Therefore, long curved bones with large radii of curvature are amenable to the three-point fixation principle when the implant occupies at least 80% of the canal diameter, providing sufficient rotational stiffness and bearing compression loads often without fatigue failure. In contrast, in a shorter long bone with an opposing double curve, such as the clavicle, with mid-diaphyseal clavicle fractures at the medial curvature and the transitional inflexion zone, without a direct linear access to the medullary canal is challenging to negotiate with a rigid intramedullary implant. Moreover, when a longer working length of the spanning implant is required across the fracture to achieve three-point fixation of the major fragments. However, this can be achieved by selecting the appropriate antegrade or retrograde approach based on the fracture site, thereby leveraging the tapering distal section of the CRISP-G **(for details, see Part 8 of the series)**.

The leading 3.5 mm or 4.5 mm taper of the CRISP-G has a smaller pitch thread, and the trailing 5.5 mm major diameter thread has a larger pitch. The central smooth shaft allows effective sliding for controlled approximation of the major fragments, adds strength, fills the canal, reduces fatigue failure, and avoids shear stresses and irritation of the healing endosteal callus at the fracture site. The smooth surface allows necessary micromotion and provides space for the secondary callus. Reamed bone debris can extrude and accumulate around the smooth intermediary segment in the fracture gap, or a circumferential cancellous bone graft can be laid subperiosteally during an open procedure. The gentle, progressive taper facilitates passage of the leading end of CRISP-G through the transition zone and the medial curvature of the hyperbolic paraboloid clavicle without sudden hoop stresses and microfractures during insertion, though these can still happen.

Selecting the appropriate CRISP-G length and diameter, along with the correct insertion approach, reduces the distance between the two nearest bone-implant contact points on either side of the fracture, thereby minimising the working length required to bridge the fracture. This provides the best interference fit, stability and flexibility for bone healing. It maintains reduction, clavicle length, interfragmentary gap, and sufficient axial and rotational stiffness. When an appropriate CRISP-G with either a right- or left-handed screw thread is chosen, the unwound implant on arm elevation under 90 degrees returns to its original tightness upon descent, remaining stable at rest until a healthy callus is established.




Figure 2. Top from left to right trailing head end, leading end; Bottom hexagonal head

CRISP-G features a self-cutting differential thread, and the blunt leading end of the implant prevents inadvertent cutting into the far cortex (**Fig. 2**). The hexagonal screw head thrusts against the cortex to adjust the interfragmentary gap. When the correct length and diameter are chosen, the head acts like the locking hasp of a classical draw bolt, strengthening fixation of the fractured fragments, and the trailing threads of a well-seeded implant resist implant extrusion. The external hexagonal head, combined with the internal hexagonal socket, creates a hybrid design that increases the engagement surface area for the dedicated screwdriver, allows torque to be applied without slipping, and prevents stripping when removing a well-fixed CRISP-G.

Choosing the correct direction of pin insertion and the intra-fragmentary pin length also provides an effective working length and the required rigidity-to-elasticity balance for the construct, thereby protecting against excessive bending loads, torsional forces, and in situ fatigue failure of the pin. The choice between biomaterials, Titanium alloy or 316-L Stainless Steel, adds another variable in terms of relative flexibility or rigidity, altering the stiffness and strength of the construct and the quality of the secondary callus for early fracture healing.

5.0 CRISP-G and surgical morphology of the clavicle:

The hyperbolic paraboloid biomechanical architecture of the clavicle is a primary deterrent to trauma surgeons' acceptance of a straight, rigid intramedullary implant despite its frequent use since the early 1940s (Murray, 1940). Based on the site and pattern of clavicle fracture, the CRISP-G lends itself well to the segmenting of the clavicle's anatomy into ten stations, guiding a surgeon to an antegrade (sternal end) or retrograde (acromial end) approach to achieve maximum length engagement of the far fracture fragment, thereby enhancing the stability and strength of the construct. The tapered design facilitates safe passage of the implant over the guide wire along the curved path of the clavicle, minimizing hoop stresses as it passes through the eccentric, variable-diameter circular and oval cross-sections of the central diaphysis.

Although clinical and radiographic measurements of the clavicle are not exact, if the selected CRISP-G matches the length after fracture reduction and the prepared canal diameter for an interference fit with the pin, the prominence of its head, soft-tissue irritation, pain and wound complications can be prevented. At the time of wound closure, bury the head of the implant deep within the periosteal, muscle, and deep fascial layers rather than leaving it subcutaneously. At the sternal end, if the head is in line with the pectoralis ridge and buried under the periosteal origin of the Cleidobrachialis pectoralis, it will be away from the Subclavius tendon. It is unlikely that any harm will come to the subclavian vessels passing posterior and inferior to the clavicle during arm elevation.

6.0 Design features for the extraction of CRISP-G:

Biologically, it is preferable to remove all fracture repair implants once the fracture has healed. Do not consider such a surgical intervention a "second surgery" as a complication of the index procedure. There is no such definition of the "second surgery". A second surgery is performed when the surgical intervention becomes necessary following a failed index procedure because of pin extrusion or implant failure before the fracture has healed, inability of the implant to support physiological loads, excessive overlying tissue irritation producing pain that limits the rehabilitation programme, wound discharge with or without superficial infection, angular deformation or breakage, non-union or refracture following the implant removal, or any other condition requiring revision surgery. Removing a repair implant following a healed fracture is not a surgical complication; it cannot be categorised as a second surgery.

The hexagonal design of the CRISP-G head discourages habitual use of a strong needle holder, needle-nosed pliers, and similar improvisations that tend to skid off well-implanted hardware, causing unnecessary soft-tissue damage and metal debris in the wound. The dedicated hybrid socket screwdriver for the extraction of the CRISP-G prevents easy disengagement of the male-female elements, thereby reducing stripping and metal shedding during implant removal.

In summary, cannulated CRISP-G has multiple engineering design features that enable closed reduction and internal fixation of a fractured clavicle. A longer engagement and a larger diameter provide stability, strength, stiffness, and relative rigidity for secondary bone healing, reducing implant breakage by providing a smooth shaft at the fracture site and well-supported screw threads within the medullary canal of the main fragments, thereby lessening the risk of implant breakage. A larger pin diameter provides an interference fit, greater resistance to torsional loads, and translational shear stresses that resist telescoping of the fragments, migration, and extrusion. The self-cutting differential screw threads clear debris and achieve a controlled approximation of the fractured ends without compression of the fracture fragments. CRISP-G would offer a higher surgical therapeutic index than the currently available intramedullary and plating systems.

Surgical therapeutic index = Cure rate/complication rate




Figure 3. SIDHI-G, the cannulated intramedullary implant prototype, and an interlocking partially threaded screw.

7.0 Self-drilling intramedullary double-helix implant ²(SIDHI-G[®]):

The unique feature of SIDHI-G is the double helix shaft in its intermediate section (**Fig. 3**). The design of SIDHI-G, including the material properties, the diameter of each tine of the spiral forming the double helix, the pitch and the major diameter, together determine its mechanical properties under load. The cannulated self-cutting and reaming tool at the leading end of this cannulated device forms part of the implant length. The reaming end has two cutting flutes: one with a forward-cutting reamer action to create the medullary canal, and the other with a reverse-cutting action for implant removal.

The profile of the cannulated hexagonal head end bears against the oblique cortical surface to strengthen and stabilize the construct. The double helix with opposing spiralling tines functions as a two-in-one right-handed and left-handed screw device. The spirals shorten during forward-compressing motion, and increasing the major diameter results in a bone-implant interference fit. Theoretically, the differential relationship between the two spirals will allow minor adjustments in the clavicle length, interfragmentary gap, and strain via forward and backwards screwing motion, which may alter the bone-implant interface by decreasing or increasing hoop stresses. A Titanium alloy or Stainless-steel double-helix shaft can provide variable strain to the construct by adjusting material properties, tine thickness, and helix pitch. The helix acts like a compression-and-tension spring under load. Therefore, excessive winding and tightening can cause rebound and extrusion. The inclusion of the sub-capital screw thread enables engagement of the implant into the near cortex, preventing extrusion. The interstices between the helical tines can be used to apply partially threaded unicortical interlocking screws (**Fig. 3**).

With good interfragmentary approximation of the fragments, due to the axial compressibility, tensile extensibility, and bending properties of the helical section, there will be a natural graded reduction in the interfragmentary strain as the secondary callus increases. In addition to increasing the helix diameter with the final controlled compression torque, the increased shear forces at the bone-implant interface, interfragmentary distraction, telescoping, and rotation due to torsional forces can be prevented by applying the included interlocking partially threaded unicortical screws proximal and distal to the fracture. The interlocking screws would also reduce the working length and increase the strength and stiffness of the bone-implant construct without compromising the required micromotions at the fracture site.

Without the interlocking screws, the device will exhibit variable resistance to torsional forces and translational shear stresses, as it is a translational fit rather than an interference fit implant. The biomechanical load-sharing

² SIDHI-G is the intellectual property of the author.

behaviour (*response and effect at the fracture site under load*) of SIDHI-G will vary with the quality and quantity of the circumferential callus and with its bending and polar moments at the fracture site.

The same technical steps apply to insert the cannulated SIDHI-G intramedullary device as to CRISP-G, as described in part 8 of the study. A similar peri-operative protocol applies to immobilizing the extremity in a shoulder immobilizer, with follow-up and implant removal at the earliest, based on the radiographic and clinical union of the fracture.

8.0 Fracture reduction and intramedullary stabilization kit ³(FRISK-G[®]):

FRISK-G is a general-purpose intramedullary system for fracture reduction and stabilization, suitable for the flexible fixation of long bones in children and adults. It is equally applicable to simple mid-diaphyseal fracture patterns of the clavicle. The FRISK-G design for the clavicle fractures can be pre-contoured to follow the curvature(s) of the clavicle anatomy, whether introduced antegrade or retrograde, depending on the site of the diaphyseal fracture.



Figure 4. FRISK-G Stainless steel prototype.

8.1 Design features:

The FRISK-G is a solid intramedullary implant (**Figure 4**). The general design is reminiscent of a bicycle spoke. The head end has a 90-degree bend with a hemispherical knob. The leading end is curved and tapered, with a blunt, rounded tip to break the trabecular plates and columns. The curved back surface of the leading end is smooth and round, helping the FRISK-G ⁴pin slide easily, skidding over the rough surface of the medullary canal and helping steer it through the curved space and displaced fracture ends. The opposite inner surface has 3-4 blunt fishhook barbs to engage into the cancellous bone of the far end fracture fragment. Although the presence of fishhook barbs is a dangerous design feature for the fixation of the clavicle fractures when crossing over to the far fragment, they provide anti-rotating and anti-sliding action once engaged into the far fragment. The blunt terminal end prevents easy penetration of the cortex.

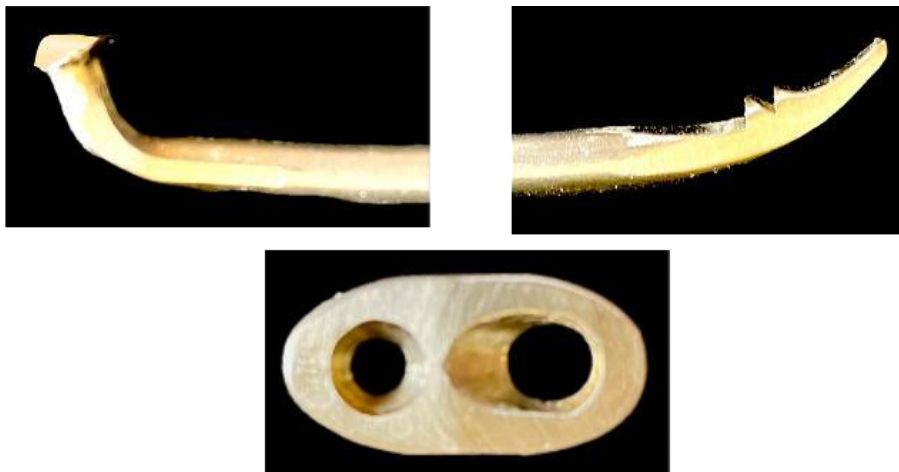

Figure 5 Coupling plate, knobbed headend and leading blunt barbed end.

The features of the head end are associated with a miniplate, which is an antimigration coupling unit of FRISK-G (**Fig. 5**). It prevents uncontrolled implant migration into the medulla and extrusion of the head under the skin. The plate engages the head end of the implant, fixing it to the bone surface, with a single unicortical screw. The surface of the coupling plate features a round countersink for a locking screw and an oval countersink with a channel to guide the trailing end of the device deep into the cortex and seat the hemispherical knob in the countersink. Once

³ FRISK-G is the intellectual property of the author

⁴ A wire has a maximum diameter of 2.5 mm; a pin has a maximum diameter of 6 mm; and a nail has a diameter exceeding 7 mm.

the thrust bearing plate is well seated on the cortex, the provided unicortical locking screw, in its countersink, holds the construct in place.

8.2 Biomechanical principles:

The FRISK-G is based on the principles of the Rush intramedullary nailing system (Rush, 1951). If too soft, an intramedullary pin or nail will bend during insertion, resulting in minimal stiffness to the bone-implant construct. On the other hand, if it is too hard, it will not conform to the curved medullary anatomy, and very high hoop stresses will cause microfractures at the entry cortex and at the fracture ends when negotiating the gap along a curved path. The implant material, such as Stainless steel, would need annealing to match the resilience of the bone, so it is stiff enough to allow reduction, maintain the realigned anatomy and the shape of the clavicle, and provide load-sharing capacity. Alternatively, a properly graded Titanium alloy will maintain the load-sharing properties of the progressively healing fracture.

The curved, smooth, rounded back drives the FRISK-G rapidly along the curved medullary canal of the clavicle and deflects the pin, guiding it across the displaced fracture fragment. Driving the pin by gentle swivelling movements helps prevent sudden penetration of the implant into the soft tissues at the fracture gap and avoids breaching the cortex. Carefully follow the leading end at the fracture site under the image intensifier and set the terminal end preferably in the centre of the medulla to engage the barbs with the trabecular network, helping resist torsional forces in conjunction with the head in the coupling plate. Thrusting of the head end against the cortex and coupling plate will prevent the pin's extrusion.

Selecting the correct length, canal-filling diameter, and pre-contouring of the implant for a given clavicle will ensure an interference fit and greater resistance to torsion, vibration, and translational shear, preventing telescoping of the fragments.

8.3 Insertion technique:

The technique for inserting FRISK-G follows the same steps as CRISP-G, using the reduction tool to prepare the medulla for the solid implant. Leave the guide wire as a placeholder and for provisional fixation to prevent displacement. Select the correct length and 80% canal-filling diameter of FRISK-G, string the coupling plate, and slide it alongside the guide wire, following the convex curve first facing anteriorly and then gradually turning it to follow the native curve along the centreline of the clavicle, using a swivelling action to prevent excessive rotating movements of the fragments. Advance the leading end at the fracture site under an image intensifier, so that the barbed surface faces anteriorly or superiorly in the prepared medullary canal. Terminate the leading end in the centre of the medulla or directed anteriorly, remove the guide wire and engage the barbs into the trabeculae without pushing the tip against the endosteum. Check the central position of the leading end and length of the implant under the image intensifier in two planes.

The draw bolt principle applies, ensuring that on either side of the fracture site, the implant length is 3-5 times the diaphyseal diameter. Seat the FRISK-G in place and embed the head end in the plate before fixing the plate, seated on the bone surface, with the unicortical locking screw. The trailing end complex must be buried under the periosteum and the overlying deep tissues.

8.4 FRISK-G removal:

At the time of extraction, the plate and knobbed end provide a firm hold in a dedicated holding instrument for the implant after the locking screw has been removed. Remember that the barbs do not engage or harm soft tissues during the implant extraction.

9.0 Closing arguments:

The kinematics of the clavicle are precise and far more sophisticated than those of other long bones. More than 10% shortening of the clavicle significantly affects scapular kinematics (Kim et al., 2017). Even unilateral disturbance in the clavicle's anatomy and biomechanical architecture disrupts the function of the entire pectoral girdle. As a two-bone mechanism, the malunion of the clavicle alters the shared kinematic arrangement with the scapula. If left uncorrected, the malunion of the clavicle causes a proportional degree of winging and dyskinesia. The ptosis of the shoulder on the affected side creates a height discrepancy between the right and left shoulders, which causes pectoral girdle disequilibrium, depending on the degree of shoulder imbalance. The persistence of frustum formation, shoulder height asymmetry, and shoulder imbalance can significantly affect coronal balance, resulting in hidden truncal imbalance and a constant struggle to maintain an erect head and neck posture relative to the median sagittal plane, and horizontal gaze. Compared with the contralateral side, the altered inclination of the malformed clavicle alters the obliquity of the glenoid fossa following the direction of the tilted scapula due to shoulder rotation, leading to an imbalance of shoulder musculature, which is not much different from the scoliosis deformity. However subtle it may be in the case of a malunited clavicle, it certainly requires a treating surgeon's attention.



The congruence of the scapulothoracic synsarcosis is jeopardized by the imbalance of forces between the Serratus anterior and the Occipitocleidal trapezius; the latter lifts the scapula upwards while the former's forward traction is reduced, leading to scapular winging (Ludewig & Reynolds, 2009). Asymmetrical action of the muscles, and altered ligamentous and deep cervical fascial tension, with disruption of tensegrity across the median plane impair the function of the proprioceptive receptors: muscle spindles and Golgi tendon organs; hindering the transmission of spatial information and normal responses, thereby affecting the posture-maintaining reflexes (Blecher et al., 2017). The coronal imbalance will be reflected in sitting posture, working on a keyboard, and writing, particularly among right-handed patients, with right-sided clavicle malunion. This hidden postural struggle, so far unrealized, causes altered bilateral force distribution and weakness, long-term discomfort, deep aching, and early fatigue of the pectoral girdle. There is no known exact method yet known to assess the changing degree of ptosis in the early few days following clavicle fractures, except the changing direction of the coracoid process like a compass needle, when pectoral girdle muscle tone returns to normal, repositioning fracture fragments, indicating the need for surgical intervention. The shoulder height discrepancy cannot be ignored as merely a body image problem.

The clinical relevance of recorded functional outcomes for shoulder and upper extremity scores related to the glenohumeral articulation is hard to validate when applied indirectly to the kinematics of the clavicle acting through the translatory motion at the scapulothoracic synsarcosis. Fortunately, the biomechanically important architectural factors, such as radii of curvature and the torsion and version angles of the clavicle when altered, are compensated over time by recovery of the muscle fibre length-tension relationship or adaptation to the new moment arm lengths and muscle function, with rehabilitation. In clinical studies, when collecting data for reporting, ignoring the loss of final few degrees of the range of motion as statistically insignificant denies the attainment of preinjury performance of the glenohumeral articulation in cases with below-average scores. In addition, measuring the functional kinematic outcome of the glenohumeral articulation as the surrogate of the clavicle kinematics can be inconsistent and imperfect, which means a lack in understanding of the clavicle's power transmission cranking machinery.

Several effective management options are available for successful surgical fixation of long bone fractures. Although the clavicle is classified as a long bone with a diaphysis (*between or across physes*), it is anatomically unlike any other long bone. The application of the long bone plating system is widely regarded as the "gold standard" for complex, fragmented fracture patterns of the clavicle. Given that the disruption of the clavicle's cranking hyperbolic paraboloid biomechanical architecture presents a unique challenge, fracture-synthesis implants used elsewhere for long bone fractures cannot be considered the gold standard for clavicle fractures. Furthermore, the well-recognized biomechanics-related biological principles of the plating system, whether in an absolute rigid state for primary bone healing or biological fixation in a relatively stable state, may not always be applicable to clavicle fractures.

A golden strategy entails numerous experimental undertakings to address problems related to bone-specific biomechanical architecture and topographic anatomy. At the same time, if it leads to serious complications, such as skin irritation, wound breakdown, stress shielding causing bone loss, refracture, etc., then it is hardly a gold standard (*the best available, unbiased method, which is not perfect, is most reliable, reproducible and validated; resulting in rapid healing, minimal pain, and restoration of function. However, it is driven by averaged statistical numbers based on predefined desirable clinical endpoints rather than ensuring patient-specific, predictable functional outcomes, often free from conflicts of interest*). The gold standard for fracture management varies by bone, for example, tension band wiring for olecranon fractures and intramedullary nailing for femoral shaft fractures. It varies with regional anatomy, bone's anatomy and its biomechanical architecture, and fracture site and pattern. Even the simplest of operations, when performed well, can have a complicated post-operative course. If this is due to an incomplete understanding of biomechanical architecture and dynamics, it is a mistake not to profit from the experience as an essential lesson in fracture surgery.

Precisely, the "gold standard" is a state of attainable perfection that requires no further research and development to improve in each context. However, this is not yet the case in the management of clavicle fractures. The literature remains strongly in favour of conservative treatment for the right and the wrong reasons. If given enough time and a healthy biological environment, all fractures heal without medical intervention. In the case of the clavicle, the essential goal is the restoration of its length, curved and torsional anatomy, and the recovery of intrinsic biomechanical architecture, thereby returning the scapulothoracic and acromioclavicular synsarcoses to normalcy; in turn, the glenohumeral articulation attains full range of overhead movements and the strength and power to perform the task in hand.

9.1 What about the conservative treatment:

"If the two fragments are in the same room, they will heal." (Rang M et al., 2005). Of course, fractures also heal in the jungle (Apley & Solomon Louis, 1982). There are several traditional designs of soft-material devices, and more recent designs made of semirigid, non-extensile fabrics, that can counteract gravity but cannot apply sustained longitudinal traction to a transversely lying bone at varying angles in the transverse and coronal planes to pull it to its correct length. They cannot correct its curvatures or remedy the variable diaphyseal torsion and version angles.



The design of soft immobilizing antigravity devices does not reduce displaced fracture fragments or maintain their alignment for long periods. Since the time of Hippocrates, it has been recognized that maintaining the reduction of displaced fractures in soft splints is almost impossible; therefore, a certain degree of residual deformity is the norm(Lester, 1929).

Patients treated conservatively frequently complain of shoulder height discrepancy, a local bump and tenderness, and pain, particularly when lying on the affected side, and there is a higher incidence of non-union than with surgical treatment. They may also experience nerve compression on abduction due to thoracic aperture syndrome and paresthesia from irritation of the brachial plexus by bulky callus formation around the overlapping ends of the fracture fragments. There is difficulty in lifting weights exceeding 9 kg above shoulder level. Refusal of delayed surgical intervention, reduced range of shoulder motion, and persistence of adverse symptoms due to shortening of the clavicle have been reported as unsatisfactory patient-based outcomes(Hill et al., 1997). Post-traumatic shortening of the clavicle up to 13 mm does not seem to cause any adverse effects, which is less than 10% of the average length (145 mm) of the clavicle(Hill et al., 1997).

9.2 In favour of well-engineered intramedullary implants and principles for their application:

The intramedullary internal fixation device for clavicle fractures was first introduced in 1940(Murray, 1940; Perry, 1966). Since then, the intramedullary implants of various designs, from simple Kirschner wire modifications to threaded Steinmann pins, smooth Titanium elastic nails, fully threaded AO screws, cannulated partially threaded AO lag screws, and headless Herbert-type solid and cannulated screws for compression have been introduced, with growing success and acceptance for the realignment and stability of the clavicle fractures. At the same time, small-diameter smooth K-wires, Titanium elastic nails, and threaded Steinmann pins have proven troublesome because of migration, sharp cut ends, tenting the skin, causing irritation, skin breakdown, serous discharge with or without superficial wound infection, and extrusion, leading to the early removal of the failed implant. These issues have cast doubt on the success and feasibility of intramedullary implants.



Figure 6. A modified Kirschner wire(Perry, 1966) with a loop at one end for an anti-rotation screw, preventing migration and extrusion of the wire.

Three points were emphasized as early as 1966 for stability and to prevent of extrusion, with cost-effective implant extraction upon fracture healing(Perry, 1966). They were to 1. adopt two-cortex fixation to keep the fracture fragments in contact, 2. prevent migration and extrusion, and 3. perform an office extraction. The simple, improvised pin design was a modification of the K-wire, with a loop at one end to secure a locking screw and the leading trocar end to engage the endosteal surface (Fig. 6).

The design of any intramedullary implant should resist clavicle shortening, prevent angular deformity and frustum formation, and avoid absolute rigidity, thereby, allowing biological fracture healing. It is up to each surgeon to apply Orthopaedic engineering principles to restore the anatomy and biomechanical architecture by applying extrinsic forces to reduce the fracture and retain the length of the clavicle. The implant should maintain the optimal interfragmentary gap and tolerable strain in the healing granulation tissue and woven callus, using the best-sized fixation implant to safely secure early function and allow a return to work. Excessive compression leads to bone resorption, continually increasing the gap and strain, fracturing the delicate callus, and delaying healing. The implant must withstand controlled mechanical stress and early movement without losing alignment.

Unlike fractures of other weight-bearing long bones, such as the femur, where stable, load-sharing intramedullary devices are used, excessive early mobilization in the case of the clavicle fracture with a semirigid fixation can prove counterproductive. Nevertheless, delaying active mobilization beyond 3-4 weeks may lead to muscle atrophy and may reduce the range of motion. The fear of stiff joints within a few weeks of immobilization is unfounded unless there is an associated joint injury and haemarthrosis(Bohler, 1930). Early mobilization is safest in patients with a stable fracture pattern and stable fixation. Caution is advised for complex fracture patterns where stability might be compromised. An individual rehabilitation program should be recommended to promote early recovery and improved outcomes.

For intramedullary techniques, large incisions are unnecessary. When making small incisions for minimal access surgery, take great care to place them accurately, and, if needed, use an image intensifier to avoid inadvertent injury to adjacent neurovascular structures. Maintain good control of the perforating awl or drill bit for depth and follow the direction of the curved medulla and eccentric course of the rudimentary canal of the clavicle. The intramedullary implant should always be inserted from the side of the smaller fragment to gain a firm hold while controlling its

rotation. Engaging the smaller fragment and employing the reduction tool or implant as a joystick to enter the far fragment is much easier. The basis for smaller fragment entry first aligns with anatomy and the biomechanical architecture of the clavicle given in Part 8 of the study for selecting an antegrade or retrograde approach. For secure fixation, secure the implant length engagement of 3–5 times the outer diameter of the fractured ends, on either side of the fracture, to achieve better purchase in the curved segments. Select a pin with the largest possible major diameter that the curved medulla will accept without causing microfractures due to hoop stresses that will jeopardize the cortical tube integrity. The insertion angle determines and fixes the trajectory of the pin. Therefore, it is best to choose the shorter fragment and make an entry under the image intensifier.

Before extracting an intramedullary implant, check for clinical signs of delayed healing and non-union, as well as radiographic signs of an interfragmentary translucent fracture line in the callus. Early removal can lead to angulation and significant clavicle shortening. Close follow-up helps prevent implant bending and fatigue fractures and facilitates timely removal. It is appropriate to investigate the biological and biomechanical causes of the new pathology and to act in a timely manner for the second surgery. It is critical to rule out infection in cases of delayed or non-union and to wait for the secondary placement of a new implant. The second insertion of a larger implant can be performed using the closed technique, as the medullary canal is already present after implant removal. Expand the canal by reaming or curetting necrotic debris to freshen the endosteum and promote its healing.

It is justifiable to open the fracture site when reduction is difficult due to the interposed soft tissues. To reconstruct the medullary canal, it is necessary first to fix the large butterfly fragment. Continuing to struggle risks damaging the vital neurovascular structures closely associated with the curved anatomy of the clavicle. A careful blunt dissection at the fracture site avoids injury to the branches of the Supraclavicular nerve. Gross dissection, rapid flushing of the fracture site, and excessive stripping of the injured periosteum are unnecessary. Leave the fracture haematoma undisturbed as much as possible, as it contains essential cellular and biochemical elements for fracture healing. After reconstructing the medullary canal, proceed with the closed reduction and fixation technique.

Fracture reduction and realignment with intramedullary fixation involve gently impacting the implant to achieve an interference fit. The implant generates variable intramedullary forces, depending on its cross-section and the elastic modulus, to counteract the inherent forces of the bone and fracture deforming extrinsic muscles. At the same time, the implant resists the external bending, tensile and torsional forces acting at the healing fracture site during early passive and active range of motion. The load-carrying capacity depends on the implant's material properties, the integrity of the fractured ends, the interfragmentary gap, tissue strain tolerance, the strength and stiffness of the bone-implant construct, and the developing callus. Shorter pins with smaller diameters provide poor stability, strength, and stiffness, leading to higher strain, and potentially delaying healing or resulting in non-union.

The cross-sectional anatomy of the double curved clavicle with an eccentric medullary canal is highly variable. Therefore, a uniform bone-implant interference fit throughout its length is practically impossible. Balancing the intrinsic static and dynamic fracture-deforming forces acting on the load-sharing intramedullary implant is essential, particularly during early fracture healing. This requires careful assessment of the fixation quality to ensure adequate external immobilization for an appropriate period, rather than the surgeon being eager to mobilize too early, driven by literature and patient demand or too late, lacking confidence. Optimal interfragmentary gap and tissue strain can stimulate osteogenesis, whereas excessive strain and early mobilization disrupt granulation tissue, predisposing to delayed union.

Broad exposure for plating technique inevitably injures the periosteal blood supply to the cortex, particularly at the fracture ends, and along the third-fifth and fourth-fifth diaphyseal sections of the clavicle. The main blood supply to the superior surface of the middle third, between the muscle attachments, is through the branches of the Supraclavicular artery and the Thoraco-acromial trunk, which penetrate the Cleidobrachialis pectoralis and Cleidobrachialis deltoideus muscles (Havet et al., 2008). One or two nutrient arteries limit the endosteal blood supply, and further injury to the already injured periosteum at the fracture site predisposes it to delayed and nonunion. In contrast to plating systems, intramedullary devices have fewer adverse effects and are preferable for maintaining bone vascularity.

Plating systems tend to be more expensive than intramedullary devices, because they require more components and instruments, thereby increasing the implant cost for healthcare facilities. The average price in US dollars for application and removal of plates is significantly higher than for intramedullary fixation of clavicle fractures, at \$2955 and \$1874, respectively (Hanselman et al., 2016).

9.3 Biology and biomechanics of fracture mode and fracture fixation modality:

High velocity, fracture fragmentation, and extrinsic factors acting at the fracture site, and patient-specific and patient-appropriate management strategies, are important determinants of clavicle fracture outcomes (Gandhi, 2022; Robinson et al., 2004). Usually, all types of fractures heal successfully. Only 10% of all fractures tend to take longer to heal and may progress to non-union (Steiner et al., 2014). Several mechanical and biological factors



determine successful fracture healing. Provided the biology is favourable, mechanical conditions at the fracture site determine the fate of a given fracture, based on management strategies and the surgeon's experience.

Current fracture management algorithms and the experience of the treating surgeons have not yet aligned with the clavicle's intricate three-dimensional biomechanical architecture. Under physiological conditions, strain dependent interfragmentary axial, bending, and torsional shear stresses, which vary with type of fracture and stabilization method, play a vital role in fracture healing (Gardner et al., 1997). External shoulder immobilizers, collar and cuff, figure-of-eight strapping, type of plating, and intramedullary implants for relative and rigid fracture fixation show varying degrees of predominance in one or more planar interfragmentary motions. Intramedullary devices preserve fracture site biology. Compared with plating, they show greater interfragmentary bending, axial and torsional shear movements at the fracture site and implant-bone interface within the medulla (Wehner et al., 2011).

The role of intramedullary shear stresses in fracture healing remains unclear. However, in the clavicle, preservation of periosteal blood supply at surgery, initial relative immobilization, and subsequent patient-induced biomechanical forces during passive and active range of motion influence fracture healing and patient-specific remodelling of the maturing callus. In fracture healing, micromotion is associated with the type of fixation and implant design. Under experimental external fixation conditions, interfragmentary micromotion of less than 0.4 mm favour early healing (Claes et al., 1995). Variable axial (compression) stiffness and translational shear stresses during fracture healing under normal biological conditions with flexible fixation yield the best healing outcome (Steiner et al., 2014). Compared to a smooth intramedullary device, a threaded intramedullary device limits excessive interfragmentary axial compression and translational shear movements, thereby promoting accelerated healing by producing moderate circumferential callus. In an intact clavicle, stresses are concentrated in the middle, where flexural rigidity is minimum (Favre et al., 2011). In midshaft fractures fixed with either an intramedullary differential screw implant or a spiral plate, both types show higher bone stresses compared to an intact clavicle (Zhang et al., 2019). However, intramedullary fixation consistently transmits higher bone stresses, concentrated at the fracture site, in cantilever and axial torsion modes than the plate, thereby promoting bone healing (Zhang et al., 2019). In contrast, higher stress distribution at the sternal and acromial end screws of the plate results in an adverse stress-shielding effect. In addition, with rigid fixation and absolute stability, bone healing and remodelling are extremely slow due to the "cone-cutting" process, resulting in a significantly higher refracture rate following plate removal than with the semirigid intramedullary implant. Little or no callus formation is unphysiological and detrimental to fracture outcome.

In contrast, a large volume of callus is equally unphysiological, often seen as a hypertrophic callus, and is proportional to mechanical stimulation that produces greater strain for a given interfragmentary gap. From a biological perspective, revascularization from preserved periosteum and soft tissues is more relevant to fracture healing than endosteum (Triffitt et al., 1993). Only the technique of closed fracture fixation with intramedullary devices can offer greater preservation of the periosteum led vascularity of the bone, and biological fixation.

9.4 The stalemate outcome or another fiasco:

Following conservative treatment of the clavicle fractures, shortening of more than 18 mm in males and 14 mm in females is associated with pain, weakness, and dysfunction of the glenohumeral joint; brachial plexus symptoms with overhead abduction; and muscle fatigue, which are recurrent themes in the literature (Lazarides & Zafiropoulos, 2006). Statistically, in most clavicle fractures, the controversy concerns conservative versus operative management on mid-term and long-term follow-up. Technically, the functional outcomes of current surgical treatments are not significantly better than those of conservative management for displaced clavicle fractures (Ban et al., 2021; Biz et al., 2023). In neither case has the normal anatomy and biomechanical architecture been restored to achieve normal kinematics of the pectoral girdle and the glenohumeral articulation. Secondly, using the functional scores of the glenohumeral articulation as a surrogate for judging the functional outcome of the clavicle is misleading.

Abandoning a clavicle fracture fixation early to allow natural healing, based on the current relative indications, often delays recognition of a new fracture pattern development, which alters the pathological anatomy. This benignly delays patient-specific treatment and ignores the practice of patient-appropriate medicine. Denying patient-specific treatment is equivalent to delaying justifiable treatment. The reason for such a denial is inadequate radiographic assessment of the fracture pattern in an antigravity device and a faulty initial perception of the anatomical form and shape of the clavicle. It is neither S-shaped nor sigmoid, nor does it resemble the sigma or the italic letter *f*, with sharp acute curves that have so far deterred wider application of intramedullary devices. The clavicle is 'claviform', greatly resembling the swan's neck, with individual variations. Secondly, the busy topographic anatomy on its posterior and inferior aspects often makes operative intervention challenging, with fears of iatrogenic injury, implant-related skin irritation, and superficial and deep surgical wound infection. For many, the surgery for clavicle fractures in adolescents seems a futile effort because the literature supports conservative management.



Based on numerous studies of clavicle fracture fixation, including on-lay and intramedullary implants, both implant designs are safe and yield comparable outcomes. Both can be readily recommended. Many studies warn that a delay in surgical intervention results in poor outcomes without improvement in symptoms of pain and fatigue. When the indicated surgical treatment is denied, the injured person does not regain strength and power at the glenohumeral joint after delayed surgery. In adolescents, treat the clavicle fractures non-operatively when undisplaced or minimally displaced in all planes, without axial rotational deformity, and with less than 8% shortening without angulation, and least likely to develop frustum formation during follow up period. Each patient should be managed according to patient-specific criteria and patient-appropriate medicine (Gandhi, 2022). Instead of following an algorithm for clavicle fractures during the acute period, it is best to review individual fracture patterns with additional plain radiography and/or computed tomography at the end of the first-week post-injury to determine whether to continue or discontinue the conservative management.

9.5 Removing a fracture repair implant is not a complication:

Gradually, as the fracture healing progresses and the circumferential callus volume increases, both strength and its polar moment of inertia increase, enabling the bone to bear greater loads than the load-sharing intramedullary implant alone. Ultimately, when the intramedullary implant becomes redundant, it is time to remove.

"It is not the purpose of osteosynthesis to permanently replace a broken bone but to provide temporary support to allow early functional rehabilitation with healing in a proper anatomical position" (Ito & Perren, 2007).

The purported statement in the literature that calls implant removal a complication is unwarranted. Including such unwarranted parameters as complications in statistical calculations significantly skews the data, unjustifiably and unfavourably (Wijdicks et al., 2013). It is against the expansion of indications for the use of certain implants. It generates unnecessary controversy, slowing advances in scientific innovations.

9.6 Evidence-based medicine is a cause of concern for unresolved malunion issue of the clavicle:

A recent large retrospective case-control study using data from the Danish National Registry contended that "patients with a previous clavicle fracture did not have an increased occurrence of receiving a diagnosis of subacromial pain syndrome compared to matched controls" (Nyholm et al., 2024). The finding was presented without a strong argument that protraction of the scapula, uncorrected shoulder ptosis, is a major risk factor for the development of the syndrome. The recorded incidence of clavicle fracture was 76 per 100,000 persons per year between ages of 18 and 60. The study did not stratify the cohort of 21,993 cases by age to rule out age related changes in the anatomy of the acromion that may contribute to impingement syndrome symptoms, nor did it consider the effects of overhead manual occupations or overhead throwing activities, instead, it relied solely on clavicle fractures. This suggests that displaced clavicle fractures are not essentially the cause of "subacromial pain syndrome," unless associated with scapular protraction and/or the individual is predisposed due to a particular preexisting variety of acromion. Thus, adding the pre-existing compromised pathological anatomy of the acromion to the list of the relative indications for surgical intervention. The indication requires either prior radiographic evidence or a specific imaging technique to evaluate the concentric space of the acromioclavicular joint in cases of clavicle fractures with shoulder ptosis. In the cases of shoulder ptosis, a standard Zanca view does not provide an optimal image for evaluating the concentric space in two planes.

In the same study, 1614 cases underwent surgery to repair the fractures between 21 and 700 days post-injury. After 365 days, more than 60 patients underwent conversion to surgical intervention. Statistically, although these 60 patients accounted for only 3.7% of the operated cases, the nature of their suffering cannot be quantified. Ignoring the suffering of such patients has been a problem for evidence-based medicine principles since its origin in 1991 (Guyatt Gordon H, 1991). Those treated conservatively initially were presumed not to be severe based on current relative indications of receiving surgery. Those who received surgery 21 days later, not considered severe enough, were benignly ignored to let heal naturally by conservative methods, according to current evidence-based medicine literature. It is a matter of recognizing the unstable clavicle fractures from the stable in an arm sling in the first place.

The current "relative indications" for surgery, namely 100% displacement of the fragments and absolute 20 mm clavicle shortening in all cases, ignore individual morphometric parameters of the clavicle and associated deformations. Again, this is an iatrogenic problem arising from evidence-based decision-making. It is not easy to predict the future course of a fracture in an individual, and prioritizing surgery beyond the currently accepted categories based on flawed evidence-based medicine, is misguided rather than recognizing patient-specific fracture patterns. The three-planar horizontal topology of the clavicle relative to the body's median plane makes it difficult to obtain true anterior-posterior and medial-to-lateral axial views. In addition, there is an incomplete understanding of its three-dimensional biomechanical architecture. Those who receive surgical care after 21 days have a higher incidence of subacromial pain syndrome, a patient-based problem. They suffer because of a poor understanding of the late outcomes of increasingly severe complications of clavicle fractures, such as soft tissue

contractures, which alter tensegrity of the region and beyond, and malunion in the form of less than 8-10% of proportional shortening and unrecognized axial deformities.

A new post-traumatic finding of subacromial impingement syndrome and the development of associated pathologies of the pectoral girdle following a clavicle fracture or a prior diagnosis of acromial pathology are progressive disorders that cause pain, limited range of motion, fatigue, and reduced strength of the glenohumeral articulation during arm elevation. Limitation of glenohumeral joint movement in any one plane restricts movement in other planes, with or without carrying weights. Bilateral normal anatomy and biomechanical architecture of the clavicle, articulating to the first thoracic vertebrae through the manubrium and the synchondrosis of the first costal cartilage and the first rib, form the foundation of the normal functioning of the entire pectoral girdle. The usage and demands placed on the clavicle by humans far exceed its current biomechanical architecture, which supports the underhand precision and high-velocity overhead cocking posture required to accelerate a projectile to hit the selected target.

10.0 Conclusion:

This nine-part study of the clavicle has sought to address its ontogenetic, anatomical, and biomechanical objectives to support the judicious application of intramedullary devices and to introduce newly conceived implant designs with theoretical underpinnings.

A revolving straight finger can easily draw a wide-based cone. However, even a few degrees of flexion at the proximal interphalangeal joint prevent this because of the constraints imposed by the flexor and extensor muscles of the finger. Likewise, the clavicle faces similar mechanical limitations in cases of frustum formation. The muscles attached to the clavicle restrain its motion as their line of action changes, altering the length of the moment arm and direction. In addition, the distorted deep cervical fascial contractures and malunion impair the function of the Subclavius, and an angular malunion further restricts its range of motion. More seriously, axial rotation and screw motion around the longitudinal screw axis, together with rolling around the pitch axis, obliterate the end range of shoulder joint movements. The loss of regular curvatures and axial screw twist reduces mechanical advantage and obstructs the gathering and release of an adequate amount of elastic strain energy in the substance of the clavicle.

Changes in screw twist and varying diaphyseal torsion angle alter the torque during clavicle healing, as the clavicle assumes a new angle of torsion and version. The screw axis becomes nonaxial with greater angular malunion of the diaphysis, and there is a loss of axial relationship between the medial and lateral curvatures, with a change in their offset angle. Usually, the axial torsion in a healthy clavicle wraps around its screw axis, which runs between the centroids of the sternoclavicular and acromioclavicular joints, thereby stabilizing the clavicle and the joints. The longitudinal screw axis of the clavicle between its constrained ends is analogous to the axis in a machine screw between the screwdriver and a workpiece. Imagine driving a screw at an angle into the workpiece while the screwdriver is at an angle, unless the screwdriver has a flexible shaft and the screw is well supported.

The clavicle is not a guardrail, and its curves are not merely to circumvent the lung apex and neurovascular structures. The offset between the medial and the lateral curvatures and the inferior curvature places the scapula on the dorsolateral aspect of the thorax. Whenever a clavicle fracture results in malunion of any degree, both the clavicle and scapula will develop dyskinesia. The scapula will have to endure the actions of a malunited clavicle, which fails to place the glenoid face congruently under the humeral head, loses the concentricity of the acromioclavicular synsarcosis, and being unable to prevent the subacromial collision. With increasing angular malunion, subacromial impingement becomes an inevitable source of pain in the anterior and lateral aspects of the shoulder. Over time, wear of the synovial sheath of the long head of the Biceps brachii sends pain down to the wrist because of Hunter's law.

A fracture of the clavicle is an intricate two-bone problem. As the loss in length of the clavicle progresses, the scapula acquires a greater degree of malposition, becoming clinically visible as scapular "winging", resulting in scapular dyskinesia. Scapular dyskinesia will affect the timing of glenoid fossa positioning, disrupting the scapulohumeral rhythm. Most often, there is an alteration in the anatomy of the medial and inferior curvatures; the lateral curvature is affected less often. The malunion progressively disturbs the congruency of the scapulothoracic synsarcosis, with loss of concentricity at the acromioclavicular synsarcosis.

Malunion of the clavicle fractures is an iatrogenic problem. It cannot be described as benign neglect when attributed to natural healing in a collar-and-cuff or figure-of-eight bandage, according to evidence-based medicine. Given the variable anatomy of the clavicle, a set of two solutions, conservative and operative management, requires critical assessment of the individual fracture pattern and a thorough understanding of its biomechanical architecture.

At the end of the first week, as the acute pain abates, the fracture pattern, previously obscured by the muscle spasm, reveals the resting position of the fragments. Without arm support under gravity, make a definite decision based on patient-specific and patient-appropriate medical facts about managing the fracture. Isolate the stable fracture configurations from the unstable. This will help develop individual management strategies, including



whether to continue conservative management. Decide without financial consideration or surgical time restrictions. The patient deserves knowledge-based surgical expertise and patient-specific fracture treatment based on fracture mechanics and pathological anatomy. Not what evidence-based medicine has to say. It is time to remove the blinkers of meta-analysis and systematic reviews.

"If you always do what you've always done, you'll always get what you've always got," said Henry Ford.

Declaration: This is to declare that the design and development of the CRISP-G, SIDHI-G and FRISK-G are the intellectual properties of Dr. Harjeet Singh Gandhi.

Conflict of interest: The author declares no conflict of interest.

Funding: The author received no financial support for the research, travel, authorship and publication of this 9 Part series.

References:

- Apley, A. G., & Solomon Louis. (1982). *Apley's System of Orthopaedics and Fractures* (6th ed.). Butterworth Scientific.
- Ban, I., Kristensen, M. T., Barfod, K. W., Eschen, J., Kallemsen, T., & Troelsen, A. (2021). Neither operative nor nonoperative approach is superior for treating displaced midshaft clavicle fractures: A partially blinded randomized controlled clinical trial. *Bone and Joint Journal*, 103 B(4). <https://doi.org/10.1302/0301-620X.103B4.BJJ-2020-1636.R1>
- Biz, C., Pozzuoli, A., Belluzzi, E., Scucchiari, D., Bragazzi, N. L., Rossin, A., Cerchiaro, M., & Ruggieri, P. (2023). An Institutional Standardised Protocol for the Treatment of Acute Displaced Midshaft Clavicle Fractures (ADMCFs): Conservative or Surgical Management for Active Patients? *Healthcare*, 11(13), 1883. <https://doi.org/10.3390/healthcare11131883>
- Blecher, R., Krief, S., Galili, T., Biton, I. E., Stern, T., Assaraf, E., Levanon, D., Appel, E., Anekstein, Y., Agar, G., Groner, Y., & Zelzer, E. (2017). The Proprioceptive System Masterminds Spinal Alignment: Insight into the Mechanism of Scoliosis. *Developmental Cell*, 42(4), 388–399.e3. <https://doi.org/10.1016/j.devcel.2017.07.022>
- Bohler, L. (1930). *The Treatment of Fractures* (2nd ed.). Wilhelm Maudrich.
- Claes, L., Wilke, H.-J., Augat, P., Rübenacker, S., & Margevicius, K. (1995). Effect of dynamization on gap healing of diaphyseal fractures under external fixation. *Clinical Biomechanics*, 10(5), 227–234. [https://doi.org/10.1016/0268-0033\(95\)99799-8](https://doi.org/10.1016/0268-0033(95)99799-8)
- Favre, P., Kloen, P., Helfet, D. L., & Werner, C. M. L. (2011). Superior versus Anteroinferior Plating of the Clavicle: A Finite Element Study. *Journal of Orthopaedic Trauma*, 25(11), 661–665. <https://doi.org/10.1097/BOT.0b013e3182143e06>
- Gandhi, H. S. (2022). Patient-appropriate and patient-specific quantification: Application of biomedical sciences and engineering principles for the amelioration of outcomes following reconstruction of osteochondrotomy of the sternum to access the mediastinum. *INTERNATIONAL JOURNAL OF COMPUTERS & TECHNOLOGY*, 22, 86–113. <https://doi.org/10.24297/ijct.v22i.9229>
- Gardner, T. N., Evans, M., Hardy, J., & Kenwright, J. (1997). Dynamic interfragmentary motion in fractures during routine patient activity. *Clinical Orthopaedics and Related Research*, 336. <https://doi.org/10.1097/00003086199703000-00030>
- Guyatt Gordon H, et al. (1991). Evidence-based medicine. *ACP Journal Club*, 114(2), A16. <https://doi.org/10.7326/ACPJC-1991-114-2-A16>
- Hanselman, A. E., Murphy, T. R., Bal, G. K., & McDonough, E. B. (2016). Operative cost comparison: Plating versus intramedullary fixation for clavicle fractures. *Orthopedics*, 39(5). <https://doi.org/10.3928/01477447-20160517-04>
- Havet, E., Duparc, F., Tobenas-Dujardin, A. C., Muller, J. M., Delas, B., & Fréger, P. (2008). Vascular anatomical basis of clavicular non-union. *Surgical and Radiologic Anatomy*, 30(1). <https://doi.org/10.1007/s00276-0070278-1>
- Hill, J. M., McGuire, M. H., & Crosby, L. A. (1997). Closed treatment of displaced middle-third fractures of the clavicle gives poor results. *The Journal of Bone and Joint Surgery*, 79(4), 537–539. <https://doi.org/10.1302/0301-620X.79B4.7529>
- Imamura, T., Ogami-Takamura, K., Saiki, K., Hamamoto, A., Endo, D., Murai, K., Nishi, K., Sakamoto, J., Okamoto, K., Oyamada, J., Manabe, Y., & Tsurumoto, T. (2021). Morphological divergence in the curvature of

human femoral diaphyses: Tracing the central mass distributions of cross-sections. *Journal of Anatomy*, 239(1), 46–58. <https://doi.org/10.1111/joa.13399>

Ito, K., & Perren, S. (2007). *Biology and Biomechanics in Bone Healing*. In T. Ruedi, R. Buckley, & C. Moran (Eds.), *AO Principles of Fracture Management* (2nd ed., pp. 9–31). Thieme Verlag.

Kim, D. S., Lee, D. W., Jang, Y. H., Yeom, J. S., & Banks, S. A. (2017). Effects of short malunion of the clavicle on in vivo scapular kinematics. *Journal of Shoulder and Elbow Surgery*, 26(9), e286–e292. <https://doi.org/10.1016/j.jse.2017.03.013>

Lazarides, S., & Zafiroopoulos, G. (2006). Conservative treatment of fractures at the middle third of the clavicle: The relevance of shortening and clinical outcome. *Journal of Shoulder and Elbow Surgery*, 15(2). <https://doi.org/10.1016/j.jse.2005.08.007>

Lester, C. W. (1929). The Treatment of Fractures of The Clavicle. *Annals of Surgery*, 89(4), 600–606. <https://doi.org/10.1097/00000658-192904000-00015>

Ludewig, P. M., & Reynolds, J. F. (2009). The association of scapular kinematics and glenohumeral joint pathologies. In *Journal of Orthopaedic and Sports Physical Therapy* (Vol. 39, Number 2). <https://doi.org/10.2519/jospt.2009.2808>

Murray, G. (1940). A method of fixation for fracture of the clavicle. *Journal of Bone and Joint Surgery*, 22(3), 616–620.

Nyholm, A. M., Witten, A., & Barfod, K. W. (2024). Clavicle fractures do not increase the occurrence of later subacromial pain syndrome. A registry-based case-control study with 15–25 years of follow-up of 131.838 persons from the Danish National Patient Register. *JSES Reviews, Reports, and Techniques*, 4(2), 141–145. <https://doi.org/10.1016/j.xrtr.2024.01.008>

Perry, B. F. (1966). An improved clavicle pin. *The American Journal of Surgery*, 112(1). [https://doi.org/10.1016/S0002-9610\(66\)91560-1](https://doi.org/10.1016/S0002-9610(66)91560-1)

Rang M, Pring ME, & Wenger DR. (2005). *Rang's Children's Fractures* (Rang M, Wenger DE, & Pring ME, Eds.; 3rd ed.). Lippincott Williams & Wilkins.

Robinson, C. M., Court-Brown, C. M., McQueen, M. M., & Wakefield, A. E. (2004). Estimating the risk of nonunion following nonoperative treatment of a clavicular fracture. *Journal of Bone and Joint Surgery*, 86(7). <https://doi.org/10.2106/00004623-200407000-00002>

Rush, L. V. (1951). Dynamic factors in medullary pinning of fractures. *The American Surgeon*, 17(9).

Steiner, M., Claes, L., Ignatius, A., Simon, U., & Wehner, T. (2014). Numerical simulation of callus healing for optimization of fracture fixation stiffness. *PLoS ONE*, 9(7). <https://doi.org/10.1371/journal.pone.0101370>

Triffitt, P. D., Cieslak, C. A., & Gregg, P. J. (1993). A quantitative study of the routes of blood flow to the tibial diaphysis after an osteotomy. *Journal of Orthopaedic Research*, 11(1). <https://doi.org/10.1002/jor.1100110107>

Wehner, T., Penzkofer, R., Augat, P., Claes, L., & Simon, U. (2011). Improvement of the shear fixation stability of intramedullary nailing. *Clinical Biomechanics*, 26(2). <https://doi.org/10.1016/j.clinbiomech.2010.09.009>

Wijdicks, F.-J., Houwert, M., Millett, P., Verleisdonk, E., & Van der Meijden, O. (2013). Systematic review of complications after intramedullary fixation for displaced midshaft clavicle fractures. *Canadian Journal of Surgery*, 56(1), 58–64. <https://doi.org/10.1503/cjs.029511>

Zhang, X., Cheng, X., Yin, B., Wang, J., Li, S., Liu, G., Hu, Z., Wu, W., Zhang, Y., & Yi, K. (2019). Finite element analysis of spiral plate and Herbert screw fixation for treatment of midshaft clavicle fractures. *Medicine (United States)*, 98(34). <https://doi.org/10.1097/MD.00000000000016898>